

ORAL LIPOMA: Report of Two Cases with Different Clinical Appearance and Review.

Prof: Dr. Sankar Vinod .V¹, Dr. Arun George², Dr. Ninan Thomas³, Dr. Dheeraj Eldho Paulose⁴, Dr. Ashin Joy⁵.

¹(Professor and HOD, Department of Oral and Maxillofacial Surgery, Mar Baselios Dental College, Kerala, India)

²(Asso: Professor, Department of Oral and Maxillofacial Surgery, Mar Baselios Dental College, Kerala, India)

³(Senior Lecturer, Department of Oral and Maxillofacial Surgery, Mar Baselios Dental College, Kerala, India)

⁴(Junior Resident, Department of Oral and Maxillofacial Surgery, Mar Baselios Dental College, Kerala, India)

⁵(Junior Resident, Department of Oral and Maxillofacial pathology, Mar Baselios Dental College, Kerala, India)

Abstract: Lipomas are one of the most common benign tumours of the body, but intra oral lipomas are relatively rare. Clinical appearance may vary depending on the site and subtype of the lesion. Intra oral lesions usually won't grow much but may become sufficiently large to cause trouble in speech and mastication. Ones diagnosed the lesion should be excised and recurrence is rare. Here we present two cases of intraoral lipoma with different clinical and histopathologic picture.

Keywords: lipoma, oral lipoma, fibrolipoma

I. Introduction

Lipomas are one of the most common benign lesions of the body. But oral Lipomas are comparatively rare. It can be said that of the vast variety of tumours that can manifest in oral cavity, Lipoma and its variants have the rarest occurrence [1]. Stones in 1948 stated that "this benign tumour commonly occurs in subcutaneous tissue only, rarely occur in oral cavity". The sites reported in the head and neck region are, Buccal Mucosa, Floor of Mouth, Gingiva, Mandible, Vestibule, Maxilla and Parotid Glands [2-10]. Lipomas usually present as an encapsulated circumscribed mass or as an obvious pedunculated mass attached to the oral mucosa. Here we present a case of classic lipoma and a case of fibrolipoma with entirely different clinical appearance in two different intra-oral sites.

II. Case Report

2.1. Case no: 1

58 yr old male patient came to the oral surgery OPD with a chief complaint of swelling in relation to the right lower cheek for past 2 years. Swelling was initially half the size of the present swelling and it gradually increased in size with no h/o pain, discharge or paresthesia. He does not give any history of rapid increase or decrease in the size. Now he noticed that the swelling is gaining size.

Patient is diabetic and under medication for the same. He is a non smoker, non alcoholic and not a pan chewer. He is moderately built and nourished with normal gait and with normal general examination findings. On inspection a diffuse swelling of about 5x3cm is seen in the right lower cheek in the mandibular body region extending from approximately 1cm below the corner of mouth and extends up to 1cm below the lower border of the mandible (fig1). Antero-posteriorly the swelling extends from the mid body region extending up to a region slightly anterior to the corner of mouth. The skin over the swelling is normal. No pulsations are seen. Intra orally a diffuse swelling extends from the distal aspect of the first molar to the canine region and swelling is seen extending to the cheek. Mucosa over the swelling is normal in colour (fig: 2).

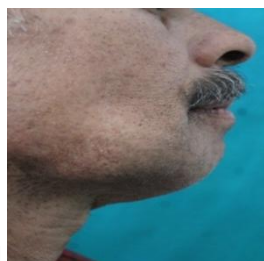

Fig: 1

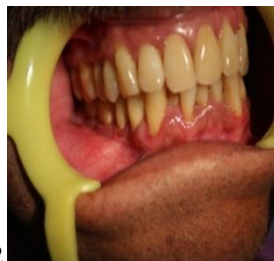

Fig: 2

On palpation swelling extends from the mid body region and anteriorly the swelling is diffuse without a definite border. Swelling extends 1cm below the corner of mouth to just below the lower border of the mandible. Swelling is soft to firm in consistency and was non tender, non compressible, non reducible with no local raise in temperature. Surface of the swelling is smooth and no fixity to skin or the underlying structures are felt. Intra orally swelling extends from the mesial aspect of second molar to the distal aspect of the canine with swelling extending to the cheek. No lingual abnormality is seen. Lymph nodes were not palpable. With these findings a provisional diagnosis of lipoma was made and the possible differential diagnosis was a fibroma, neuroma and a dento-alveolar abscess. OPG and Occlusal Radiographs were taken to rule out any associated pathology and proved otherwise. (Fig: 3&4)

So we proceeded with an incision biopsy from the buccal vestibule and the histopathology came as classic lipoma. (Fig: 5&6). Microscopic examination of the slow-growing lipoma reveals a tissue which differs very slightly from normal fatty tissue. In tumour tissue, however, there are cells rich in protoplasm and filled with small drops of fat, that is, lipoblasts. Based on this total excision under general anaesthesia was performed and histopathology of the excision specimen confirms the diagnosis.

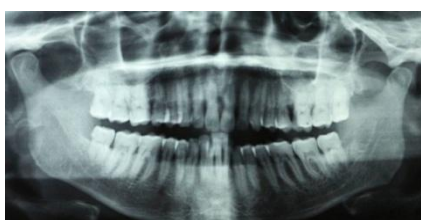


Fig: 3

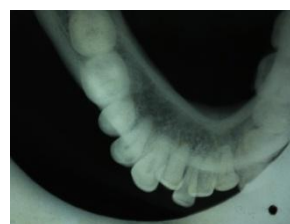

Fig: 4

Fig: 5 : 10X view

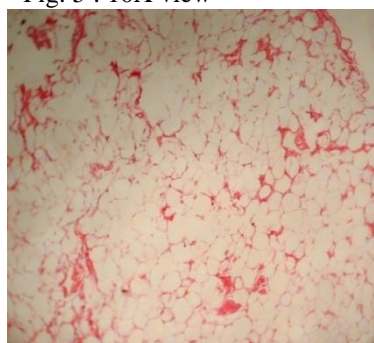
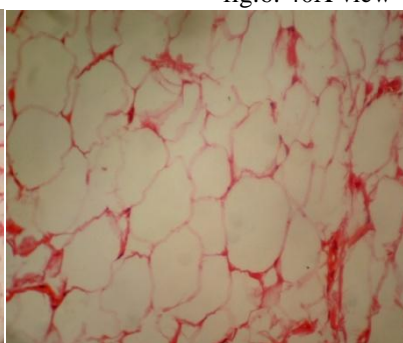


fig:6: 40X view

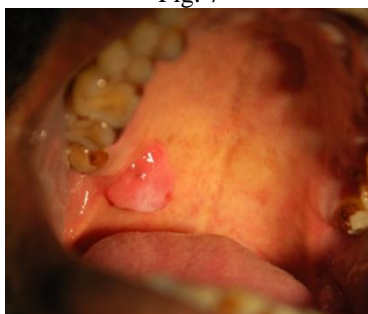

2.2. Case no: 2

46 year old male patient presented with a chief complaint of swelling in the throat for the last 6 months. Initially the swelling was very small in size with gradual increase in size. He gives a history of trauma to that region with some sharp food particle and after that only he noticed the swelling. He had no pain initially but now he experience pain while having food.

His medical, dental and personal history was non contributory. His general examination was within normal limits. On inspection a swelling of size 2x1 cm was noted in the junction of hard and soft palate close to the palatal aspect of the third molar tooth(fig:7). Swelling is a sessile mass and dark pink in colour. The surface of the swelling is smooth and no discharge is noted. On palpation the swelling is in the soft palate which is rubbery and soft in consistency, non tender, non compressible and no fluctuation are felt. No fixity to the underlying tissue is felt. His dental examination failed to prove any foci of infection in relation to the lesion. No lymph nodes were palpable.

Fig: 7



A provisional diagnosis of irritation fibroma was made and the lesion was excised under local anaesthesia and sent for biopsy. The histopathology report came as fibrolipoma. The biopsy specimen was of size 14x12x6mm, brownish white in colour and firm in consistency. Microscopic examination showed a fibrous connective tissue exhibiting bundles of collagen fibers with spindle shaped fibroblasts. Between the collagen fibers numerous signet ring shaped adipocytes were seen (fig: 8& 9).

Fig: 8: 10X / Low power: Surface epithelium, Fibrous tissue, Adipocytes in between fibrous tissue

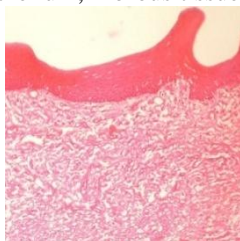
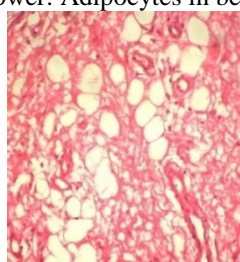


Fig: 9: 40X/High power: Adipocytes in between fibrous tissue



III. Discussion

Word lipoma is derived from two Greek words lipos and oma which means fat and tumour respectively [11]. Lipomas are called as universal tumours because of their distribution. They grow slowly and attain a particular size and remain dormant or static thereafter [12]. Lipomas are clinically classified as solitary, multiple or congenital (congenital diffuse lipomatosis). The lesion can be encapsulated or diffuse. The diffuse form is relatively rare and commonly occurs in subcutaneous tissue of the neck. The commonly occurring benign forms are encapsulated ones.

Clinically the tumour may present as a pedunculated or sessile mass, and may vary in size according to the site of occurrence. Lipomas are usually solitary in occurrence and sometimes are lobulated. Sensation of fluctuance can be elicited in some lesions. As previously stated, the lesion can arise in any part of the body where there is adipose tissue. The commonest sites are subcutaneous in the shoulder and back, sub-fascial, beneath palmar and plantar fascia, subsynovial, intra-articular, along the voluntary muscles, subserous, submucous, extradural and intra-glandular. Retroperitoneal lesions may undergo sacromatous changes and can enlarge to very large proportions. They have a tendency to calcify also. Sometimes multiple lipomas are associated with Gardner's syndrome. Adipose Dolorosa (Dercum's disease) is a term used when lipomas are associated with neurologic disturbances

Lipomas can be further divided into lipofibroma, fibrolipoma and fibrosing lipomas with respect to the quantity of fibrous connective tissue [13]. Other variants of lipoma include angioliipoma and myxoliipoma. Fibrolipoma is the commonest one with excess interstratification of connective tissue that is usually required as a supporting stroma.[14].

3.1. Review

Fibrolipoma of the free gingiva has been reported by Nicholas R. Marfino in 1959[1]. Hatziotis published a review article in 1971 and he evaluated 145 published cases of oral lipoma. According to his review total number of classic lipoma was 66% and fibrolipoma was 33%. Lipoma of the hard palate constitutes 6.2% and that of soft palate was 2.7% [15]. Robert o Greer et al in 1973 analysed 16 cases and out of which 8 were in the cheek, 4 were in the retromolar region, 2 in the floor of mouth and 1 each in peritonsillar area and hammular notch [16]. de Visscher in 1982 reviewed 851 lipomas out of which only 19 were in the oral cavity(2.4%). Out of this majority of the lesion were in the buccal mucosa and lower lip [17]. Apart from the normal appearance, many authors have reported rare incidences like bilateral multiple spindle cell lipomas of the tongue by Tomoaki Imai et al in 2008[18], intraosseous lipoma in the periapical region of the maxillary third molar by Andre Luiz et al 2011[19], bilateral asymmetric tongue classic lipomas by Sagn-Hwa Lee et al in 2012[20],

intramuscular lipoma in the masseter muscle by Go Tsumuraya et al in 2014[21], lipomas of submandibular space by Colin O'Rourke et al in 2015[22] and Oral spindle cell lipoma by Michael et al in 2015[23].

3.2. Aetiology

Lipoma can arise in any part of the body where fat or adipose cells are present. These are mesenchymal origin is due to accumulation or circumscribed collection of fat. Almost over 50% of cases are reported at the 4th and 5th decade of life and the incidence is more in females than males. The exact aetiology is still unknown. The proposed factors are hereditary, hormonal, congenital and trauma, mostly chronic trauma [12]. Fibrolipoma a histologic variant of lipoma is also commonly seen in cheeks and have female predilection. The aetiology includes metaplasia of muscle cell, fatty degeneration and origin from embryonic lipoblastic cells. Trauma, irritation (chronic irritation) and infection is also proposed [24].

3.3. Clinical features

Oral lipomas are usually soft, yellow and slow in growth. They are also either pedunculated or sessile mass. Usually are not fixed and have a liquid like mobility. They are usually undiagnosed as it will not cause any trouble to the routine of the patient and are presented to the clinician when they attain sufficient size and cause interference with normal function. As a result the history of the lesion is poorly defined by most of the patients.

The clinical difference from whole body lipoma is that intra oral lipoma has a yellowish hue as they are seen through the overlying mucosa. But in tongue, they may present deep in the muscle layer and may not have this feature. In oral cavity also the occurrence is more towards areas with abundant fat tissue like cheek and buccal sulcus. Lip and hard palate are the least common site for intraoral lipomas. As per the literature the size may vary but seldom exceed 25mm in overall measurement [12].

Lipomas which are superficial can get confused with mucocoele or ranula depending on the location while submucosal types can get confused with chronic abscess especially when they are near the dentoalveolar segment. Clinical course is usually benign, but it also can attain considerable size and interfere with speech and mastication. It is capable of producing pain and discomfort and pressure sensation and can undergo degenerative changes due to constant trauma and also have malignant potential. Fibrolipoma on palpation will be rubbery, semi-firm with poorly defined margins [24].

Lipoma originating in the maxillary antrum and body of mandible also been reported. Malignant transformation into liposarcoma is extremely rare for intra oral lipomas. The common differential diagnosis of oral lipomas is soft tissue irritation fibromas and dentoalveolar abscess depending on the site of occurrence. The presence of tumour more in females can be explained by two ways (1) due to general endocrine disturbances, mainly in post menopausal age and (2) due to frequent consultation due to concern phobia [12].

The ability to infiltrate to adjacent muscles and recur locally in case of infiltrating lipoma had a false diagnosis of liposarcoma. But the malignant tumour is characterised by areas of lipoblastic proliferation, cellular pleomorphism, increased vascularity and mitosis and these are not found in infiltrating lipoma. Also aP2 marker protein which is expressed in lipoblasts is found in malignant lesions. The lipid in lipoma is not available for metabolism which is the main difference in the normal body fat in the lipoma. This is due to the lipoprotein lipase activity which is relatively high in the tumour cells [20].

3.4. Treatment

Treatment of lipoma irrespective of type and site is complete surgical excision. If done properly recurrence is rare.

IV. Conclusion

Though lipoma is a common lesion in the body, its occurrence in oral cavity is relatively rare. Most of the times these lesions are asymptomatic till it interfere with normal functions of the body like speech and mastication. Different histologic subtypes may appear different clinically but management remains the same and if complete excision can be achieved, recurrence is extremely rare.

References

- [1]. Nicholas R. Marfino, D.D.S. Developing fibrolipoma of the free gingiva. O.S, O.M & O.P April 1959.
- [2]. Vazirani, S. J and DeVore, D. T. Fibrolipoma of the Oral Cavity; Report of a Case. ORAL SURG., ORAL MED. & ORAL PATH. 1958.11: 355-358.
- [3]. Dixon, W. R. Lipoma of Oral Cavity, ORAL SURG, ORAL MED & ORAL PATH. 3: 575-577,1956
- [4]. Bruce, K. W and Royer, R. Q. Lipoma of the Oral Cavity; Report of Three Cases. ORAL SURG. ORAL MED. & ORAL PATH. 7: 930-938. 1954.
- [5]. Blake, H., and Blake, F. Lipoma in the Floor of the Mouth: Report of a Case. ORAL SURG, ORAL MED. & ORAL PATH. 1959, 12: 1436-1438.

- [6]. Macgregor, A. B. Sublingual Ranula, Dermoid Cyst, and Lipoma, ORAI, STTRC, ORAI. MED & ORAL PATH. 1959.12: 334-342,
- [7]. Martino, N. R. Developing Fibrolipoma of the Free Gingiva, ORAL SURG, And ORAL MED. & ORAL PATH. 1959. 12: 349-352,
- [8]. Oringer, M. J. Lipoma of the Mandible. ORAL, SURG, ORAI MED & ORAL PATH. 1948. 1: 1134.
- [9]. Turner, H. Lipoma of the Lip; Report of a Case. ORAL SURG., ORAL MED & ORAL PATH. 1956. 9: 376-379.
- [10]. Quinn, J. H. Lipoma of the Oral Labial Vestibule. ORAL SURG, ORAL, MED & ORAL PATH. 1949. 2: 723-725.
- [11]. Bergenholtz, L.D.S and H. Thilander, L.D.S. LIPOMA OF THE ORAL CAVITY. OM, OS, OP. 1960. vol: 3.
- [12]. Alexander d. Rapis. Lipoma of the oral cavity. Int. J. Oral surg, 1982 : 11: 30-35
- [13]. Patrick D Toto and Nicholas Choukas. Fibrolipoma of the buccal mucosa. OM. OS. OP December 1962
- [14]. John E. Horton. Lipoma of the tongue. OM. OS. OP. June 1968.
- [15]. J. Ch. Hatziotis and Thessaloniki. Lipoma of the oral cavity. Oral Surg. April, 1971. Volume 31.
- [16]. Robert. Greer and John F. Richardson. The nature of lipomas and their significance in the oral cavity. Oral surgery. October 1973. Volume: 36.
- [17]. Jan G. A. M. de Visscher. Lipomas and Fibrolipomas of the Oral Cavity. J. max.-fac. Surg. 10 (1982) 177-181.
- [18]. Tomoaki Imai, DDS, PhD, Masahiro Michizawa, DDS, PhD, Hidetaka Shimizu, DDS, PhD, Takumi Imai, DDS, PhD, Naonori Yamamoto, DDS, and Yoshiaki Yura, DDS, PhD. Bilateral multiple spindle cell lipomas of the tongue. Oral Surg Oral Med Oral Pathol Oral Radiol Endod 2008;106:264-9.
- [19]. Andre Luiz Gomide Morais, DDS, Elismauro Francisco Mendonca, MSc, DDS, PhD, Ana Helena Goncalves de Alencar, MSc, DDS, PhD, and Carlos Estrela, MSc, DDS, PhD. J Endod 2011;37:554–557.
- [20]. Sang-Hwa Lee, DDS, PhD and Hyun-Joong Yoon, DDS, PhD. Bilateral asymmetric tongue classic lipomas. Oral Surg Oral Med Oral Pathol Oral Radiol 2012; 114:e15-e18.
- [21]. Go Tsumuraya, Hiroyuki Yamada, Hajime Shimizu, Yoshiki Hamada. Intramuscular lipoma in the masseter muscle: a case report. British Journal of Oral and Maxillofacial Surgery. 2014: 52 e2-e23.
- [22]. Colin O'Rourke, MB, MCh, Habib Khan, Fintan Wallis, MB, BCh, and John E. Fenton, MCh. Lipomas of the Submandibular Space: Case Report of a Sialolipoma and Review of Diagnostic Investigations Available. J Oral Maxillofac Surg 73:99-105, 2015.
- [23]. Michael Miloro, DMD, MD, FACS , Anastasia Haupt, DDS , Alexis B. Olsson, DDS, Antonia Kolokythas, DDS, MSc. Oral spindle cell lipoma: a rare occurrence and review of the literature. Oral and Maxillofacial Surgery Cases 1 (2015) 12e14.
- [24]. Apostolos Epivatianos, DDS, PhD, Anastasios K. Markopoulos, DDS, MS, PhD and Panagiotis Papanayotou, DDS, MD, PhD. Benign Tumours of Adipose Tissue of the Oral Cavity: A Clinicopathologic Study of 13 Cases. J Oral Maxillofac Surg 58:1113-1117, 2000.